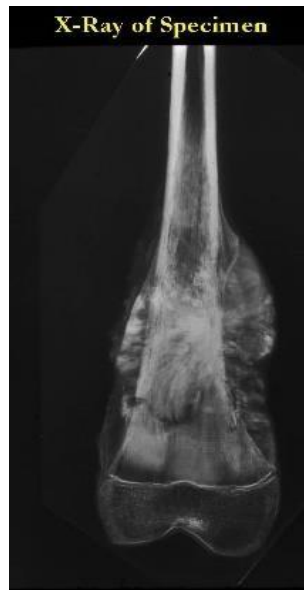
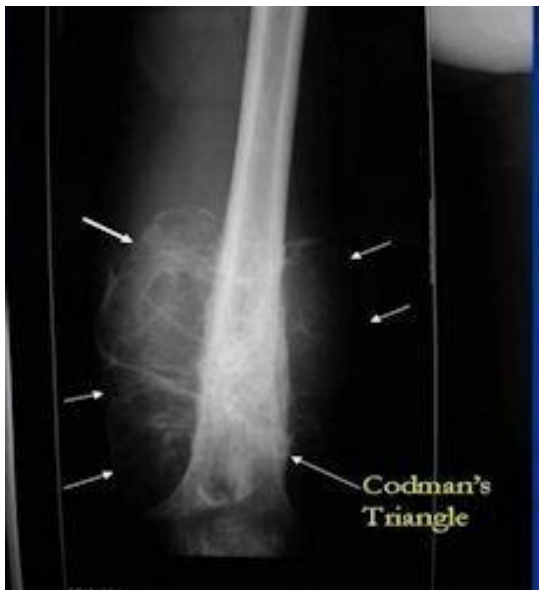

**INI- CET NOV 2020
DETAILED SOLUTIONS
ORTHOPEDICS**

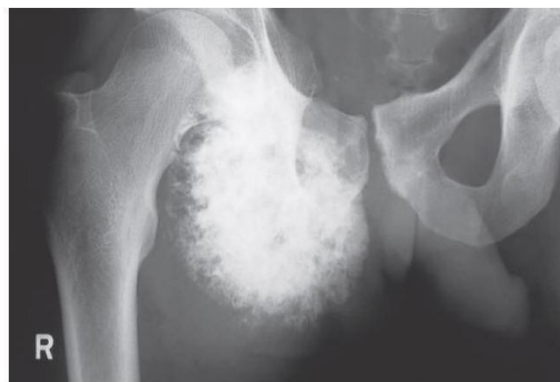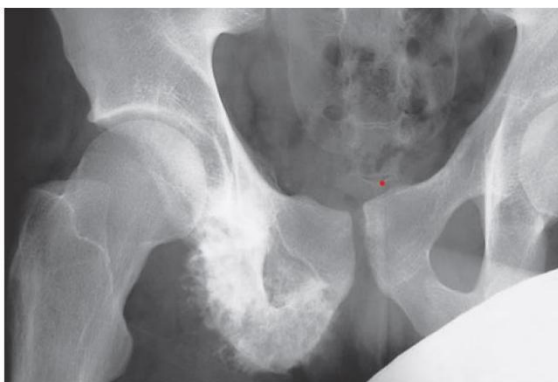Q1 IMAGE: Tumor on lower end of femur - chondrosarcoma / osteosarcoma / GCT / chondroblastoma

Ans.

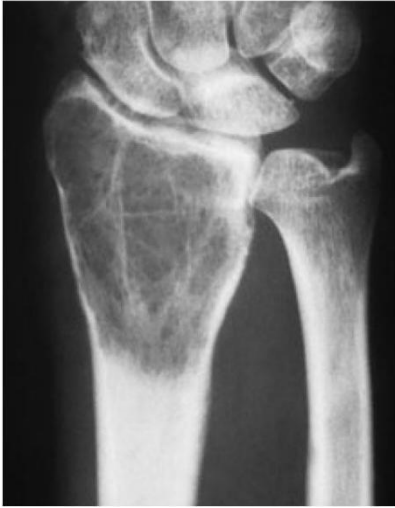Osteosarcoma: it is a malignant tumor with bimodal age distribution. Metaphyseal in origin- so the lesion will appear arising from metaphysis. X ray shows - lesion arising from metaphysis with involvement of soft tissue. Characteristic Codman's triangle and sunray appearance



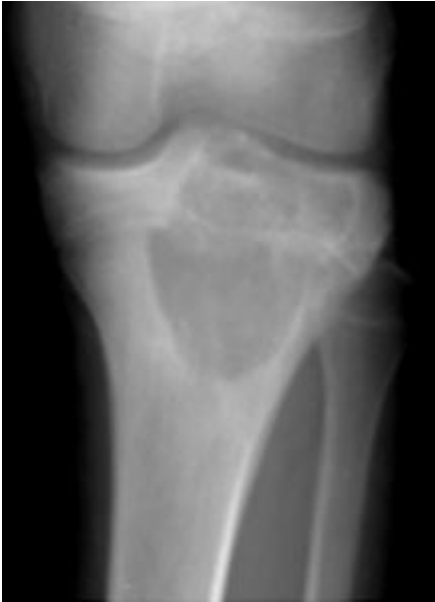Chondrosarcoma: malignant tumor with primary type occurring in flat bones like scapula, pelvis in 5th decade onwards. Secondary arises from lesions like osteochondroma. So, for a secondary chondrosarcoma to be the answer primary lesion will be shown in image mostly an osteochondroma x ray - lesion arising from flat bones, scapula of pelvis, involving the soft tissues. Characteristic - popcorn calcification



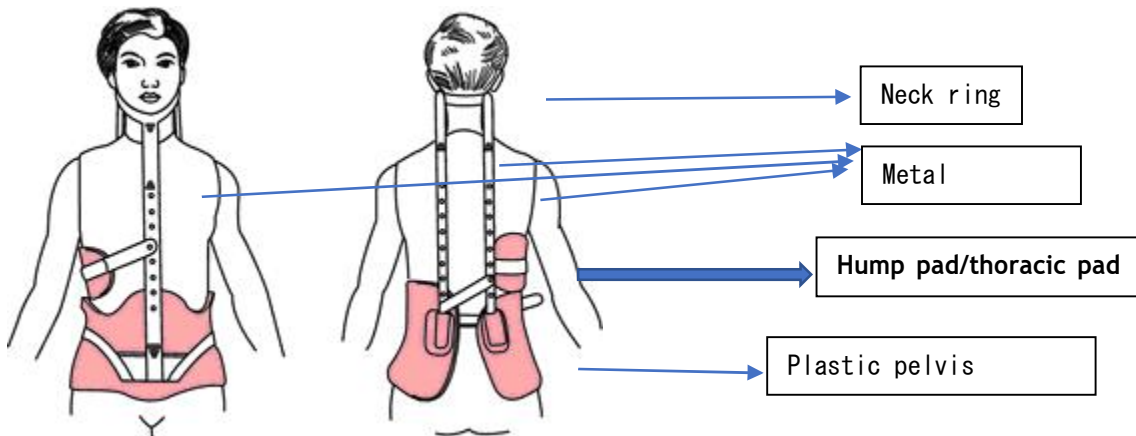
GCT: benign aggressive > locally malignant epiphyseal tumor. Classical picture would be of distal end of radius. X ray - an expansile lytic lesion with soap bubble appearance involving the epiphysis



Chondroblastoma: benign aggressive tumor. Typically, in 10-25 years old. Young - distal femur MC. old age- flat bones. Characteristic radiographic findings - Well circumscribed. Usually centered in epiphysis. Sclerotic rim present



1. Milwaukee brace -



Milwaukee brace is used in the treatment of scoliosis.

Q2 Day 5 after surgery - unable to abduct arm - root level of injury - C 2/3/4/5

Ans: abduction of arm

0-15 degrees - supraspinatus (suprascapular nerve- C5, C6)

15-90 degrees - deltoid (axillary nerve - C5, C6)

Beyond 90 degrees / overhead abduction - combined action of serratus anterior (long thoracic nerve - C5, C6, C7) and trapezius (Cranial nerve XI)

Hence the answer would be C5

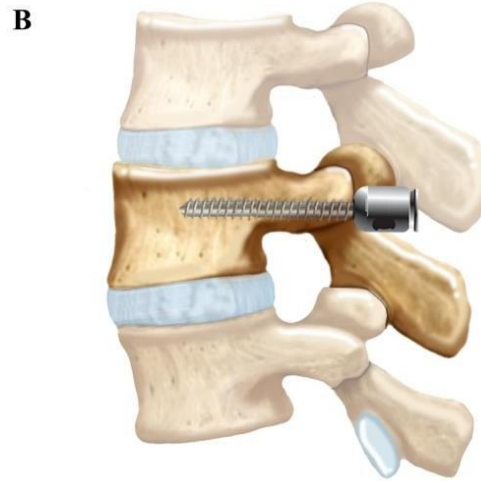
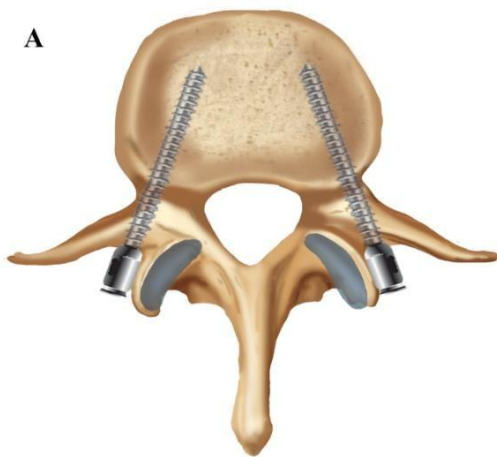
Q3 Not involved in shoulder abduction

- (A) Serratus ant
- (B) Deltoid
- (C) Trapezius
- (D) Pec major

Ans: (D) Pec major

Q4 If the doctor is fixing a screw in the vertebra - where should it be fixed:
pedicle / lamina / spinous process / facets

ANS: the pedicle is the place where a screw is commonly put, known as pedicle screw fixation.



**Q5 Substance with osteo-inductive property for non-union fracture of shaft femur:
BMP - bone morphogenetic protein / PMMA / Calcium phosphate / CaSo4**

Ans: fracture union takes place through 3 mechanisms:

1. **Osteoinduction:** means inducing the native osteogenic cells to multiply and bridge the fracture. E.g. Bone morphogenetic proteins (BMPs), autografts, demineralized bone matrix (DBM).
2. **Osteoconduction:** means providing scaffold on which the movement of native osteogenic cells occurs to bridge the fracture. E.g. calcium sulphate (CaSO₄), hydroxyapatite, tricalcium phosphate, bioactive glass ceramics.
3. **Osteogenesis:** these types of materials provide the extra pool of osteogenic cells in addition to the native osteogenic cells to bridge the fracture. E.g. autografts
- ★
4. **Best graft material: Autograft.** As it provides all 3 mechanisms of fracture healing - Osteoinduction, Osteoconduction and osteogenesis.

Q6 Which drug promotes bone formation : teriparatide/raloxifene/bisphosphonates /calcitonin

Ans: teriparatide

Major Drugs Used in Diseases of Bone Mineral Homeostasis				
Subclass	Mechanism of Action	Effects	Clinical Applications	Toxicities
Vitamin D, metabolites, analogs				
Cholecalciferol	Regulate gene transcription via the vitamin D receptor	Stimulate intestinal calcium absorption, bone resorption, renal calcium and phosphate reabsorption • decrease parathyroid hormone (PTH) • promote innate immunity • inhibit adaptive immunity	Osteoporosis, osteomalacia, renal failure, malabsorption	Hypercalcemia, hypercalciuria • the vitamin D preparations have much longer half-life than the metabolites and analogs
Ergocalciferol				
Calcitriol				
Doxercalciferol				
Paricalcitol				
Bisphosphonates				
Alendronate	Suppress the activity of osteoclasts in part via inhibition of farnesyl pyrophosphate synthesis	Inhibit bone resorption and secondarily bone formation	Osteoporosis, bone metastases, hypercalcemia	Adynamic bone, possible renal failure, rare osteonecrosis of the jaw
Risedronate				
Ibandronate				
Pamidronate				
Zoledronate				
Hormones				
Teriparatide	These hormones act on their cognate receptors coupled to G protein signaling pathways	Teriparatide stimulates bone turnover, calcitonin suppresses bone resorption	Both are used in osteoporosis • calcitonin is used for hypercalcemia	Teriparatide may cause hypercalcemia and hypercalciuria
Calcitonin				
Selective estrogen-receptor modulators				
Raloxifene	Interacts selectively with estrogen receptors	Inhibits bone resorption without stimulating breast or uterus	Osteoporosis	Does not prevent hot flashes • increased risk of thrombophlebitis
Calcium receptor agonists				
Cinacalcet	Activates the calcium sensing receptor	Inhibits PTH secretion	Hyperparathyroidism	Nausea
Minerals				
Calcium	Multiple physiologic actions through regulation of multiple enzymatic pathways	Strontium suppresses bone resorption and increases bone formation, calcium and phosphate required for bone mineralization	Osteoporosis, osteomalacia, deficiencies in calcium or phosphate	Ectopic calcification
Phosphate				
Strontium				

Q7 Drugs for multiple myeloma :

- (A) Vincristine
- (B) Vinblastine
- (C) Methotrexate
- (D) ?

Ans: (A) vincristine

Drugs used to treat multiple myeloma include:

- ❖ Melphalan.
- ❖ Vincristine
- ❖ Cyclophosphamide
- ❖ Etoposide
- ❖ Doxorubicin
- ❖ Liposomal doxorubicin

