

- Q1 If a nurse witnesses the umbilical cord coming out of the vagina in a term pregnant woman, what is the most appropriate step that the nurse should do?
- (A) Gently push the cord back
  - (B) Ask the patient to lie in Trendelenberg position
  - (C) Inform that the patient needs to be shifted for delivery immediately
  - (D) Do a vaginal exam to know the presentation

Ans: (B) Ask the patient to lie in Trendelenberg position

**Explanation:** Cord prolapse is a medical emergency. It is defined as descent of umbilical cord beyond cervix, besides or post the presenting part. Leads to high perinatal fetal mortality. The principal causes of asphyxia is cord compression and umbilical arterial vasospasm preventing venous and arterial blood flow to and from the fetus

Aim is to deliver the baby ASAP.

1. Early labour with normal fetal heart- cat 2 lscs
2. Early labour with abnormal fetal heart rate pattern- cat 1 lscs
3. Advanced labour- expedite delivery

Steps taken till delivery is awaited are- (to prevent cord compression)

1. When cord prolapse is diagnosed before full dilatation, assistance should be immediately called and preparations made for immediate birth in theatre. (RCOG- GTG)
2. Prevent cord compression by- lifting the fetal head manually or by bladder filling with 500-750ml saline.
3. Knee-chest position by mother or Trendelenberg or exaggerated sims position
4. Tocolytics can be tried for a while till awaiting delivery if fetal heart is not normal.

Here answer is that nurse should immediately put her in Trendelenberg position to relieve compression. She cannot touch the cord as it will further cause vasospasm. If questions asks in context to a doctor, then answer should be do vaginal examination to immediately decide for delivery.

Ref: RCOG, green top guideline no. 50(2014)

There are insufficient data to evaluate manual replacement of the prolapsed cord above the presenting part to allow continuation of labour. This practice is not recommended.

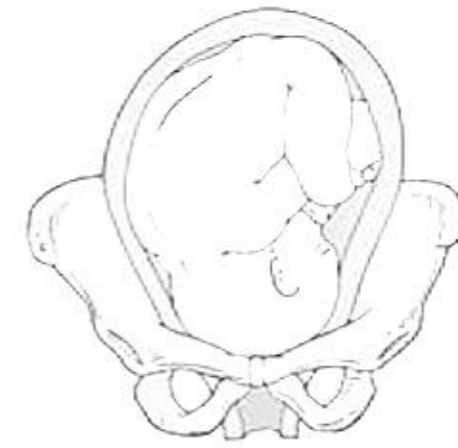
Q2 identify the position of fetal head in the image given below-

- (A) Right occipito anterior
- (B) Left occipito anterior
- (C) Right occipito posterior
- (D) Left occipito posterior

Ans. (A) Right occipito anterior

Occiput is clearly near pubic symphysis, so it is anterior.

Since you are seeing patient from front, so your right is patient's left and vice versa. So this is easily right occipito anterior.



Right occiput anterior (ROA)

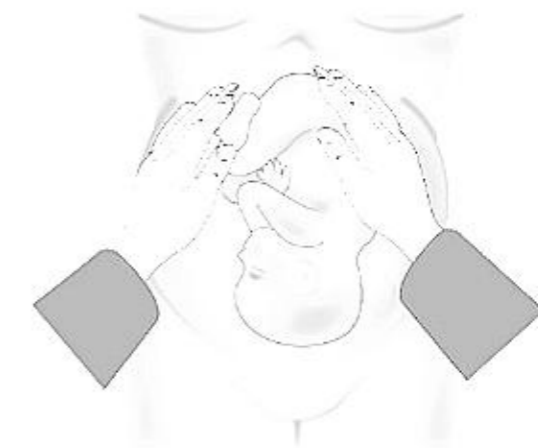
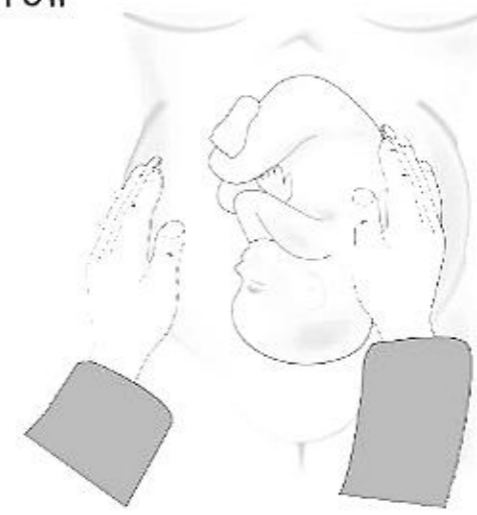Q3 Identify the grip by seeing the manoeuvre given below

- (A) Fundal grip
- (B) Umbilical grip
- (C) Pawlik grip
- (D) Pelvic grip

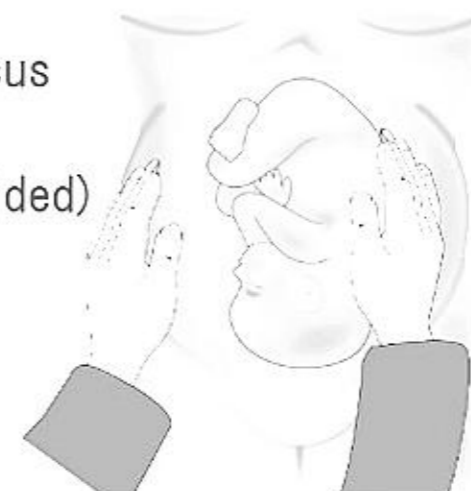
Ans. (B) Umbilical grip

Ans. 1<sup>st</sup> grip is fundal grip- hands put on uterine fundus  
Determine- fetal lie (longitudinal or transverse) & presentation

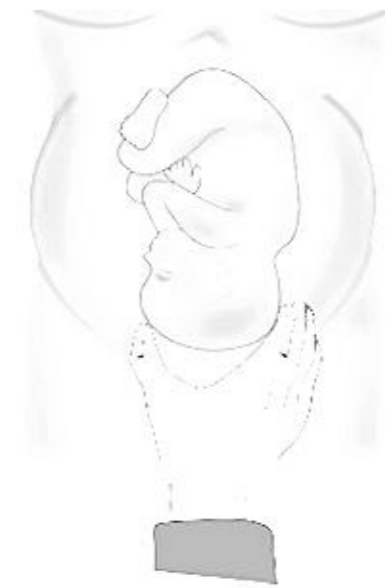(cephalic or breech)



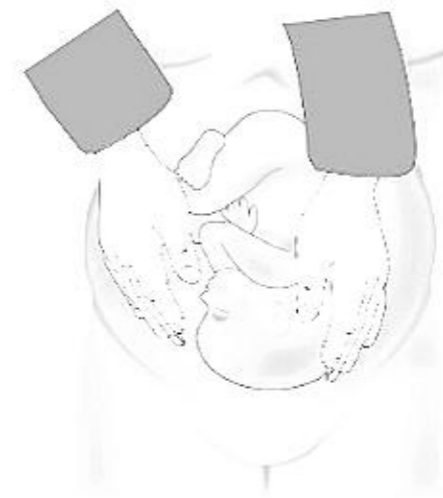2nd grip is umbilical grip- hands put besides umbilicus  
Determine- fetal position /orientation  
( if back is on left then it means occiput if left sided)



3rd grip- pawlik grip - extend your hand and put it over pubic symphysis to Grip the presenting part  
Determine- confirmation of presenting part.



4th grip- pelvic grip- put both hands along symphysis to feel parts of Fetal head Determine- degree of descent of fetal head.



#### Q4 Modified Robson' s C-section criteria

**Ans.** In 2015, WHO proposed the use of the Robson classification (also known as the 10-group classification) as a global standard for assessing, monitoring and comparing caesarean section rates both within healthcare facilities and between them. The system classifies all women into one of 10 categories .

Variables used were-

- a) Parity
- b) Onset of labor
- c) Gestational age
- d) Fetal presentation
- e) No. of fetuses.

#### CLASSES ARE -

- Class 1: Nullipara ,  $\geq 37$  weeks, single, cephalic, spontaneous labor
- Class 2: Nullipara,  $\geq 37$  weeks, single, cephalic, induced labor or CS before labor
  - i. 2a: induced labor
  - ii. 2b: CS before labor
- Class 3: Multipara, equal to or  $> 37$  weeks, single, cephalic, without previous scar, in spontaneous labour
- Class 4: Multipara,  $\geq 37$  weeks, single, cephalic, were induced previously or had LSCS before labor.

- i. 4a: induced labor ii. 4b: CS before labor
- Class 5: Multipara, with previous CS,  $\geq 37$  weeks, single, cephalic
- Class 6: Nullipara, single, breech
- Class 7: Multipara, single, breech (including previous scar)
- Class 8: all women with Multiple pregnancy (with or without previous CS)
- Class 9: Singleton pregnancy, oblique/transverse lie (with or without previous CS)
- Class 10: Single, cephalic,  $< 37$ wk ( with or without previous scar)

Q5 Suman is having recurrent trichomonas infection - she was advised PAP smear - what should be explained to Suman?

- (A) PAP is screening for cervical cancer
- (B) PAP is diagnostic for Trichomonas
- (C) PAP smear tells whether patient has cancer cervix or not
- (D) PAP detects reproductive tract cancer

Ans : (A) PAP is screening for cervical cancer

**Explanation:** This question has to be multiple correct answers type or it must have 'all correct except' in it.

Explanation as below-

Pap smear is a cytological test for screening cervical cancer.

Method- Exfoliative cells from ecto and endocervix is taken and smeared on a slide.

Fixative used is 95% ethanol. Low sensitivity-50% but high specificity.

Then cells are studied under microscope for cellular changes corresponding to cancer or pre-cancer.

What all it can detect-

1. Epithelial cell abnormality, categorised as-
  2. SQUAMOUS- ASCUS, LSIL or HSIL, Squamous cell cancer.
  3. GLANDULAR - Atypical endocervical glandular cell, Benign or atypical endometrial cells ,
  4. It can also detect VAIN(vaginal intraepithelial neoplasia).
  5. Organisms- trichomonas, fungal organisms consistent with candida, shift in flora suggesting BV, bacteria morphologically consistent with actinomyces, cellular changes consistent with herpes.
  6. Other non-neoplastic findings- Inflammation, radiation changes, post hysterectomy status, atrophy.

So, as such, A, C,D ,all are correct. But if this is the single correct answer, then best to choose is A.

Ref:-novak, 15th edition, page-1066.

Q6 All are true about breech delivery except:

- (A) Breech identified for the first time during delivery is a contraindication for normal labor
- (B) For breech delivery, continuous FHR monitoring is done
- (C) Breech delivery is done where emergency CS facility is available
- (D) Breech delivery is undertaken at a center where a birth attendant skilled in breech delivery is available

Ans. (A) Breech identified for the first time during delivery is a contraindication for normal labor

Incidence of breech presentation is 3%. If patient had one breech delivery previously, incidence of repeat breech is 10%.

External cephalic version is offered to every woman in breech (unless contraindicated)

Factors favouring caesarean breech delivery-

1. Lack of operator experience
2. Patient request for cesarean delivery
3. Large fetus: > 3800 to 4000 g
4. Apparently healthy and viable preterm fetus (fetus <2.5kg)
5. Severe fetal-growth restriction
6. Prior perinatal death or neonatal birth trauma
7. Incomplete or footling breech presentation
8. Hyperextended head
9. Contracted pelvis
10. Prior cesarean delivery

- Induction of labour is not advised in breech. Augmentation, only in c/o hypotonic contractions.
- There is higher risk of cord prolapse, so continuous fetal monitoring is recommended.
- Delivery is undertaken in a hospital with facilities for immediate delivery

Ref: Williams 25th edition, page -581

Management of breech presentation, GTG-20b (may 2017)

Q7 HPV protein - in vaccine

- (A) E6/E7
- (B) L1 capsid
- (C) E1/E2

Ans: (B) L1 capsid

HPV vaccine Gardasil, is for prevention of HPV infection, using HPV virus like proteins to generate neutralising antibodies against major capsid protein L1. To control HPV induced infection, therapeutic vaccines need to be developed for pre-existing lesions, which will generate immunity against E6 & E7 protein. 3 types of vaccines are there-

	Cervarix (bivalent)	Gardasil (quadrivalent)	Gardasil (nonavalent)
Hpv subtypes	16, 18	6, 11, 16, 18	6, 11, 16, 18, 31, 33, 45, 52, 58
Protect against	CIN, AIS	CIN, VAIN, VIN, ANAL CANCER GENITAL WARTS	CINN, VAI9N, VIN, anal cancer, AIN, warts
Recommended in	Females only	Both male and females	Both males and females
Age group		11-12yr (9-26yr)	11-12yr (9-26yr)
dose	3 doses, .5ml i/m	3 doses, .5ml i/m	3 doses, .5ml i/m
adjuvant	Aluminium hydroxide	Aluminium hydroxyphosphate sulphate (it produce higher adjuvant titre)	Aluminium hydroxyphosphate sulphate

Q8 Pregnant woman has cramps at night - what will nurse tell the patient to do?

- (A) Plantar flexion of ankle & Knee flexion
- (B) Plantar flexion of ankle & Knee extension
- (C) Dorsiflexion of ankle & knee extension
- (D) Dorsiflexion of ankle & knee flexion

Ans: (C) Dorsiflexion of ankle & knee extension

Leg cramps are very common in pregnancy. Reason-

1. Increase in weight & changes in circulation
2. Pressure of growing baby, placed on nerves & blood vessels of legs.
3. How to manage cramps-
4. Stretching (knee extension & ankle dorsiflexion)

5. Massage
6. Apply heating pad
7. Drinking lots of water & taking essential minerals - Ca, K, Mg
8. Rest with leg elevated

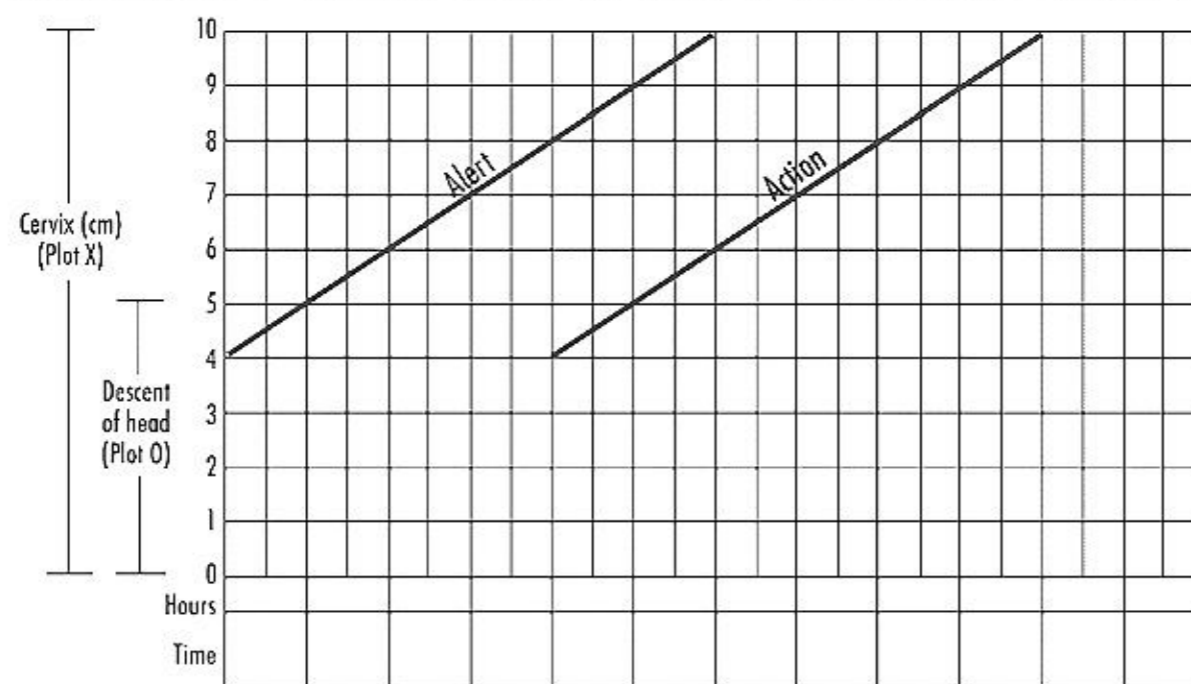
Ref: <https://americanpregnancy.org/healthy-pregnancy/pregnancy-health-wellness/leg-cramps-during-pregnancy-992/>

Q9 Partogram started when cervical dilatation is ...

- (A) 4
- (B) 6
- (C) 8
- (D) 10 cm

Ans: (A) 4

It is a graphical representation of progress of labour alongwith maternal & fetal conditions Modified partogram plotting, now starts from 4cm, as against old WHO partogram , which used to start in latent phase of labour only.



- Active phase of labour is now from 6cm , but WHO partogram has not updated that and plotting in partogram is still started from 4cm.
- 1st plot is made on the alert line , then plotting made every 4hr .
- As soon as marking crosses alert line, pt is shifted to higher centre & more vigilant monitoring started.
- On reaching action line, pt has to be delivered either via LSCS or instrumental delivery.



